

# A new modality in vein treatment: Extraluminal valvuloplasty by interventional injection of hyaluronic acid gel

Johann C. Ragg, MD

Interventional Phlebology    angioclinic® vein centers    Berlin (D) – Munich (D) – Zurich (CH)

## Background

Vein-preserving treatment of proximal saphenous insufficiency is attempted by surgical means like extraluminal stenting or grafting, by restriction to sidebranch ligation (ASVAL), or with minor vein loss by proximal ligation of the saphenous vein (CHIVA). Historic radiofrequency-based attempts of vein shrinking have not been successful (VNUS "restore"). Although physical advantages of radial beam lasers (tissue-specific absorption), it seems hard to obtain real vein wall shrinking while avoiding thrombogenic endothelium damage. Furthermore, it is difficult to irradiate the vein wall but not the valves. Therefore, today's focus is on extraluminal interventional solutions.

## Objective

As a new modality, the idea to shape veins by extraluminal injection of viscous fluids was first presented by our group at UIP 2013 in Boston. In these first steps, hyaluronan with fast bioresorption was used. Now a further study has been performed using crosslinked hyaluronan with an expected tissue persistence of > 6 months.

## Patients/Methods

In a pilot study 2 - 5/2014, 20 patients (12w, 8 m; 38 - 67 J.) with proximal valve incompetence of the GSV (diameter 7.0 - 11.4 mm, mean 8.6) were selected to receive a diameter reduction of the diseased valve zone by circumferential injection of a NASHA gel, 2% solution, crosslink degree: 2% (Fig. 1). Gel injections were performed by use of a safety system consisting of a relocatable cannula with triple-cut tip, and a flexible outer metal catheter (IntraShape®, Fig. 2). The gel injections were performed under continuous ultrasound imaging, aiming at a strictly perivenous placement. The injection was finished when reflux was no longer observed during Valsava maneuver in the standing patient. No external compression was applied. Clinical and ultrasound examinations (B-mode, B-flow, 3D-scan, color mode) were performed after 2, 12 and 26 weeks.

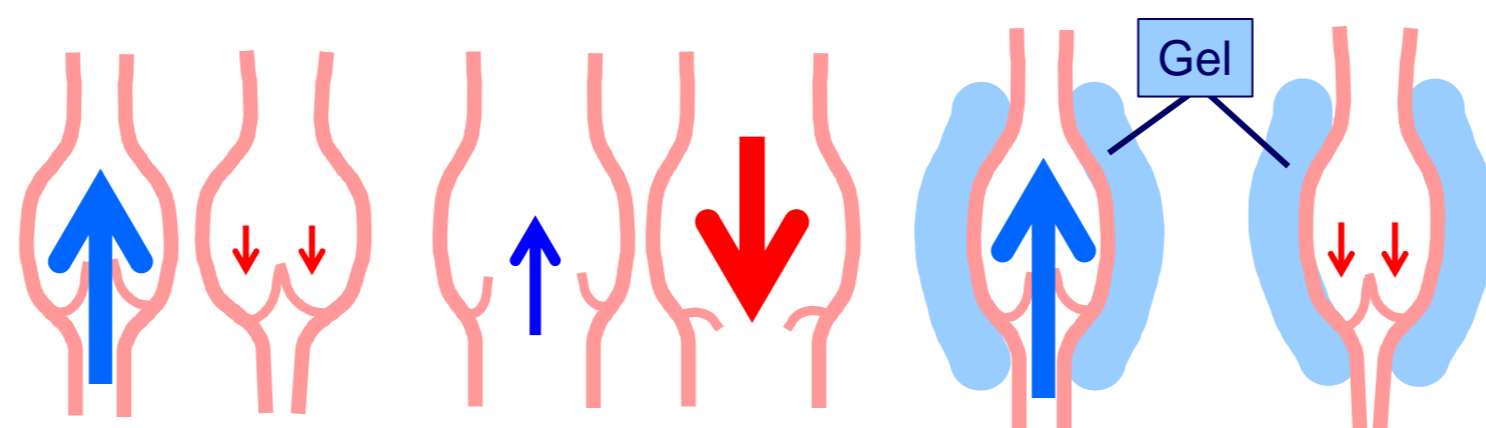


Fig. 1: a) healthy vein    b) dilated and insufficient valve zone    c) valve zone normalized

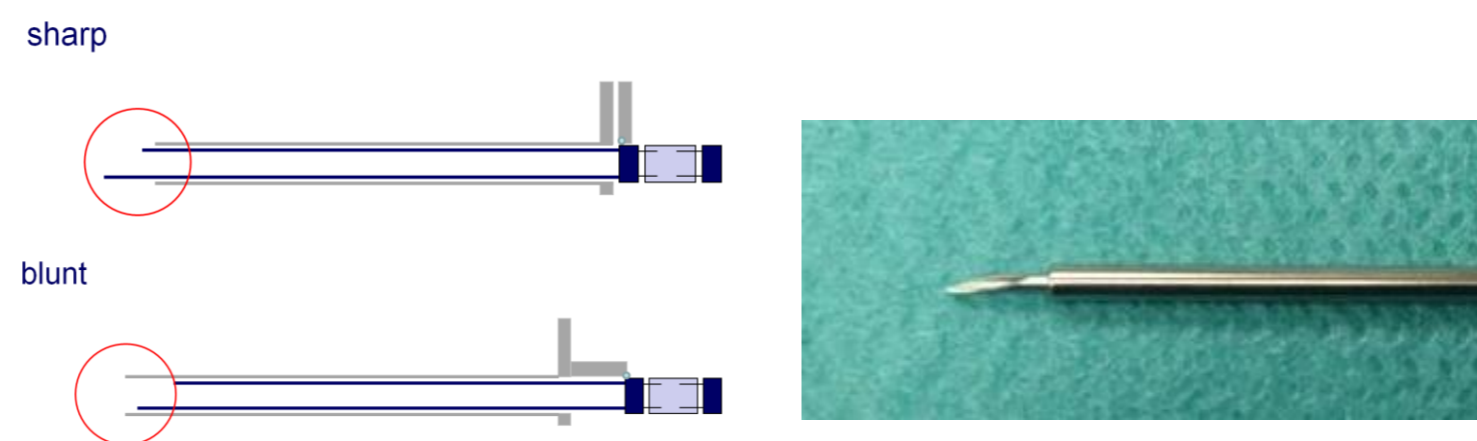


Fig. 2: Injection tool, consisting of flexible metal tubes. Outer diameter: 2.2 mm

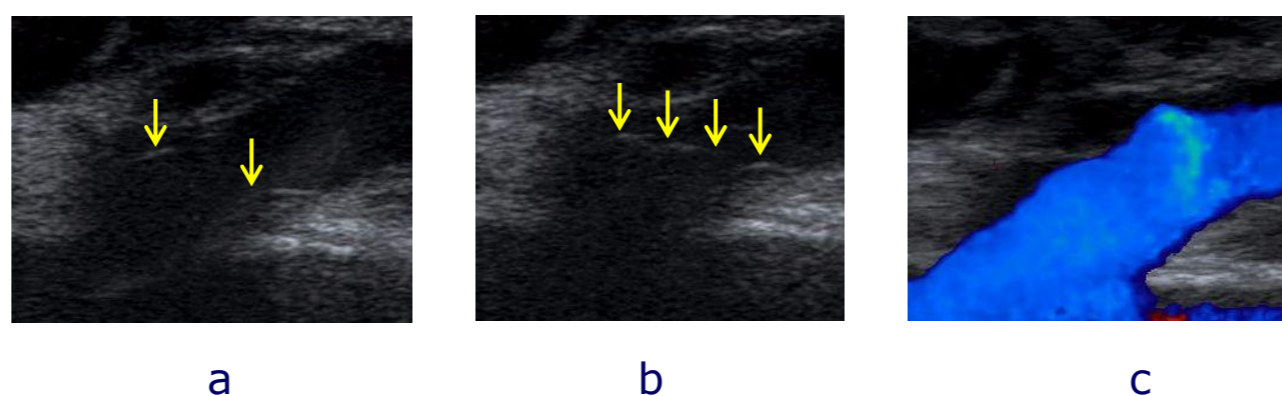


Fig. 3: Restored vein valves at week 26: a) open    b) closed    c) color flow

## Results

An orthograde flow could be established in 19/20 cases (95%) using gel volumina of 14 - 35 ml (mean: 21.3 ml). The treated segment length was 4 - 8 cm, mean: 5.1 cm.

After 12 weeks orthograde flow was present in 18/19 cases (83.3%), and after 26 weeks in 15/19 cases (78.95%). Cases with recurring reflux (n = 4) received a second gel injection of 4 - 7 ml with hemodynamic success up to week 26 (Fig. 3). There were no adverse reactions.

## Discussion

The inclusion criterion of "existent and mobile" valve structures, used in the same way prior to surgical valvuloplasty, is not distinctly relatable to functional quality, due to limited ultrasound imaging. For the same reason, in some cases it remains unclear whether there is real valve restoration or just hemodynamic benefit.

It is known that exclusion of reflux may normalize vein diameters. Although excluded in this study, the additional effects of physical means (stockings, exercise) may contribute to years of restoration without re-treatment.

## Conclusions

External valvuloplasty by perivenous gel injection is feasible and middle-term effective. It provides a potential vein-preserving option for initial stages of the disease.

Before long-term benefit can be estimated, manufacturers are challenged to provide optimized hyaluronan, and injection technique has to become more precise.